



SEPTIC PERITONITIS

Case Report
Kristina E. Perkins, DVM

REVIEWED BY
ADRIENNE BENTLEY, DVM, DACVS

Signalment:

“Gracie”

3-year-old FS Dachshund

History:

Gracie presented to an emergency clinic with a history of vomiting, a poor appetite, and a painful abdomen of several days duration. She had a negative Snap cPL test. Abdominal radiographs showed small bone fragments in the pylorus. A barium study showed delayed gastric emptying 15 hours post-administration. An abdominal exploratory was performed and revealed a normal stomach, but a 25cm segment of mid-jejunum was inflamed, edematous, and contained patches of bruising and two areas of early infarct formation. This area of jejunum was resected, and an anastomosis was performed. No foreign body was found, and no biopsy samples were submitted. Gracie presented to VMSG 5 days later for lethargy, inappetence, and abdominal distension.

Clinical Exam:

Quiet, lethargic, normothermic, tachycardic, pink mucous membranes that were slightly tacky with a CRT of 2 seconds, and strong, synchronous peripheral pulses. Five percent dehydration, abdominal distension, and free abdominal fluid were present.

Diagnostic Imaging:

Abdominal ultrasound: Large amount of echogenic free fluid. The small intestine was diffusely corrugated. The stomach was fluid distended with decreased motility subjectively. Remainder of the abdominal viscera appeared normal.

Abdominocentesis: Fluid aspirated appeared brown and cloudy. Abdominal fluid glucose : blood glucose = 49 : 86; abdominal fluid lactate : blood lactate = 5.6 : 2.6. Cytology: rare intracellular coccobacilli, many neutrophils and macrophages, occasional hemosiderin or bilirubin crystals and intracellular yellow to black pigment.

Diagnosis:

Septic peritonitis

Treatment/Management:

The patient was stabilized with a bolus of IV fluids to correct the hypovolemia. She was pre-medicated with atropine (0.02 mg/kg SC) and hydromorphone (0.1 mg/kg IM). She was induced with diazepam (0.3 mg/kg IV) and ketamine (5 mg/kg IV) and maintained on isoflurane. An epidural of Duramorph (0.1 mg/kg) was administered. IV fluids (Norm R 10 ml/kg/hr; Hetastarch 1 ml/kg/hr), Baytril (10mg/kg IV) and ampicillin (22 mg/kg) were administered intra-operatively.

The previous abdominal incision was reopened and extended. Several hundred milliliters of green-brown fluid containing ingesta, thrombi, and fibrinous material was suctioned from the abdomen. Dehiscence of the anastomosis site from the previous surgery with compromised bowel at either end was identified. Fifteen centimeters of jejunum were resected, including both ends of the previous anastomosis site, and a new anastomosis was performed. Due to the severity of the peritonitis, a modified form of open peritoneal drainage was selected. The linea alba was closed loosely in a simple continuous pattern, leaving a 1-2 cm gap between the edges. Rather than apply an absorbent bandage as is typically done with open peritoneal drainage, a Jackson-Pratt closed-suction drain was placed over the gap in the linea alba and secured with an adhesive sheet (Ioban) placed over the incision. An esophagostomy tube was placed post-operatively. The following day, the patient underwent a second anesthesia to lavage and close the abdomen; a new Jackson-Pratt drain was placed at the time of closure. The peritonitis had dramatically improved.

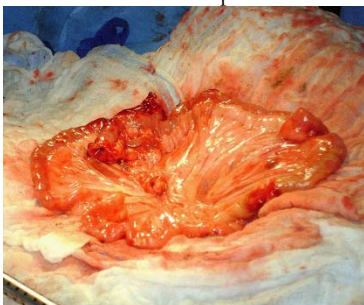


Figure 1: Dehiscence of previous resection and anastomosis

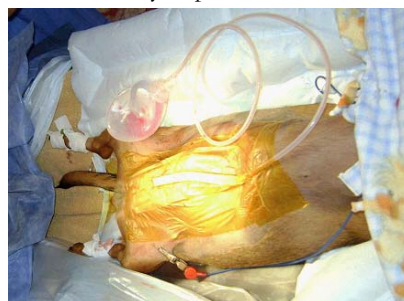

Figure 2: Modified open peritoneal drainage system using Jackson-Pratt drain

Post-operative care:

The Jackson-Pratt drain was emptied every 4 hours, and the volume of its contents was recorded. Ampicillin (22 mg/kg IV q8h), Baytril (10 mg/kg, IV q24h), metronidazole (10 mg/kg, IV q12h), famotidine (0.5 mg/kg, IV q12h), hydromorphone (0.05 mg/kg, IV/SC q6h), IV fluids (Norm R and Hetastarch), Cerenia (1mg/kg, SC), and metoclopramide (1mg/kg/day CRI) were started post-operatively. Waltham low fat canned food in a water slurry was started three days post-operatively via the E-tube. By day 4 after surgery, the patient received all medications orally, including Tramadol (2 mg/kg, PO q8h) and Clavamox (14.5 mg/kg, PO q12h). Five days after surgery, the patient began eating voluntarily. Chloramphenicol (48.5 mg/kg, PO q8h) was started 8 days after surgery to treat an *Enterococcus* species grown on the abdominal fluid culture. The patient was discharged 9 days post-operatively. On recheck exam 7 days following discharge, Gracie was reported to be doing well at home and had a normal physical exam. Her sutures and esophagostomy tube were removed at that time.

Discussion:

Septic peritonitis is a life-threatening surgical emergency. This condition necessitates an immediate diagnosis, stabilization, and appropriate therapy. The diagnosis of septic peritonitis is commonly made from the abdominal fluid cytology. Cytology alone has been reported to be 57-87% accurate and includes observing intracellular bacteria and obtaining a peritoneal fluid nucleated cell count of >13,000 per microliter [3]. Comparing the concentrations of glucose and lactate in the blood to those in the abdominal effusion can support cytological findings or be used alone to diagnose septic peritonitis. A blood glucose concentration at least 20mg/dL higher than the peritoneal fluid glucose concentration and a blood lactate concentration at least 2mmol/L lower than the peritoneal fluid lactate concentration are highly sensitive and specific for septic peritonitis in dogs [3].

Factors to consider in selecting a form of peritoneal drainage include volume of the effusion, character of the effusion, presence of gross contamination, serosal changes of abdominal organs, and distribution of the contamination and peritonitis [1]. Historically, open peritoneal drainage has been reserved for the most severe cases of generalized septic peritonitis in which intra-operative lavage alone is insufficient to remove the contamination or when ongoing septic, inflammatory processes are anticipated [4,7]. Although open peritoneal drainage is effective in draining the contaminated fluid, it is also laborious and expensive since multiple anesthetic episodes for bandage changes and a second surgery are necessary [5]. Loss of fluid, electrolytes, and protein is significant and cannot be readily quantified. There is an increased opportunity for ascending nosocomial infection and the possibility of organ herniation [1,5,6]. The decision to close the peritoneal cavity is dependent on assessment of the same factors used to select the initial form of drainage. On average, the duration of open abdominal drainage is 4.4 days (range 1 to 9 days) [6,7].

Closed suction drainage is the most commonly used technique for peritoneal drainage [1]. It creates negative pressure within the peritoneal cavity, so drainage is independent of the intraperitoneal circulation of fluid [5]. These drains are typically left in place for 2-8 days [1,5], and the volume of fluid collected from the drain can be quantified and assessed qualitatively [1,2,5]. Drains are removed when the volume of fluid collected has dramatically decreased (1-4 ml/kg/day) and when cytologic analysis shows decreasing numbers of nondegenerative neutrophils in the absence of bacteria [2]. The advantages of closed suction drainage include a lower risk of nosocomial infections, decreased potential for organ herniation, less labor and expense, and the elimination of a second surgery [5].

Vacuum-assisted closure is a modified form of open peritoneal drainage that is relatively new to veterinary medicine. The linea alba is closed loosely as in traditional open peritoneal drainage. A polyurethane sponge is applied over the gap in the linea alba. Fenestrated tubing connects the foam to a vacuum that applies intermittent subatmospheric pressure. The foam and tubing are secured under an adherent layer [1]. This device promotes wound healing by increasing blood flow, decreasing tissue edema, and removing excess fluid [1]. The advantages of vacuum-assisted closure are effective drainage with decreased frequency of bandage changes and ability to quantify and evaluate the effusion [1].

In this case, Gracie was managed with open peritoneal drainage due to the degree of contamination and peritonitis. The modified form of open peritoneal drainage using a Jackson-Pratt drain allowed effective drainage of the peritoneal cavity, the ability to quantify and evaluate the effusion, and keep the patient clean and dry without frequent bandage changes and associated sedation. This combination of drainage techniques provides the same advantages as vacuum-assisted closure, but is more readily available and easier for staff to manage.

References:

- 1) Bentley A, Holt DE. Drainage Techniques for the Septic Abdomen. In Bonagura JD, Twedt DC: *Kirk's Current Veterinary Therapy XIV*. Saunders Elsevier, St. Louis, 2009, p.72-76.
- 2) Volk SW. Peritonitis. In Silverstein DC, Hopper K: *Small Animal Critical Care Medicine*. Saunders Elsevier, St. Louis, 2009, p. 579-583.
- 3) Bonczynski JJ, Ludwig LL, Barton LJ, Loar A, Peterson ME. Comparison of peritoneal fluid and peripheral blood pH, bicarbonate, glucose, and lactate concentrations as a diagnostic tool for septic peritonitis in dogs and cats. *Veterinary Surgery* 32:161-166, 2003.
- 4) Staatz, AJ, Monnet E, Seim III HB. Open peritoneal drainage versus primary closure for the treatment of septic peritonitis in dogs and cats: 42 cases (1993-1999). *Veterinary Surgery* 3: 174-180, 2002.
- 5) Mueller MG, Ludwig LL, Barton LJ. Use of closed-suction drains to treat generalized peritonitis in dogs and cats: 40 cases (1997-1999). *JAVMA* 219(6): 789-794, 2001.
- 6) Winkler KP, Greenfield CL. Potential prognostic indicators in diffuse peritonitis treated with open peritoneal drainage in the canine patient. *The Journal of Veterinary Emergency and Critical Care* 10(4): 259-265, 2000.
- 7) Woolfson JM, Dulisch ML. Open abdominal drainage in the treatment of generalized peritonitis in 25 dogs and cats. *Veterinary Surgery* 15(1): 27-32, 1986.