



PLEURAL EFFUSION AND STERILE NODULAR PANNICULITIS IN A DOG

Case Report
ALEX ZUR LINDEN, DVM

REVIEWED BY
TODD DEPPE, DVM, DACVIM

Signalment: Lady Bug is a 4 year old, female spayed, Brittany spaniel.



Figure 1. Lady Bug

History: Five months prior to referral Lady Bug presented to her primary veterinarian for a dog bite wound on her inner right thigh that was treated with topical lincomycin, oral clindamycin and betadine lavage. Two months later the wound was not healing, and a subcutaneous lump appeared on her left flank. A pyoderma was also noted at this time. One week later the patient developed a fever of 104.2 F and a mild leukocytosis (12,000 cells/uL) and was started on ciprofloxacin. A few days later her temperature had normalized to 102.5 F, and she was started on carprofen and amikacin. Bloodwork revealed a hypoalbuminemia (1.9 g/dL) and an elevated amylase (1454 U/L) at this time. One month later a draining abscess formed on her left flank, and she was started on clindamycin. Two weeks later she was anorexic, her left flank was still draining fluid and she had a temperature of 105 F. An exploratory surgery of the left flank was performed, and a biopsy and cultures were submitted. Histopathology of the mass revealed marked multifocal to coalescing chronic pyogranulomatous steatitis and chronic pyogranulomatous inflammatory reaction with areas of necrosis and peripheral fibrosis. The culture results revealed a 4+ growth of *Serratia marcescens* and a 3+ growth of *Pseudomonas aeruginosa* that were both sensitive to multiple antibiotics. The day prior to presentation at VMSG the patient had a leukocytosis of 60,000 cells/uL and PCV 30% and was started on ciprofloxacin and TMP sulfa. By this time the patient had developed numerous oozing cutaneous wounds all over her body.

Physical Exam: On presentation Lady Bug was quiet and depressed with an increased respiratory rate and effort. She weighed 17 kg. She was dehydrated with an elevated heart rate. Lung sounds were quiet ventrally. She had a non-healing wound on her left flank that was partially apposed with sutures. Multiple scabs were present over her neck, thorax and abdomen and were oozing a clear yellow fluid when the scabs were removed.

Laboratory Diagnostics: Bloodwork performed on presentation revealed a neutrophilia (34,008 cells/uL) with a left shift (bands 3052 cells/uL), a monocytosis (4796 cells/uL) and an anemia (PCV 19%). A chemistry panel revealed an elevated alkaline phosphatase (254 U/L), hypoalbuminemia (1.0 g/dL), elevated direct bilirubin (0.4 mg/dL), hypercholesterolemia (457 mg/dL) and a hyponatremia (135 mEq/L). A spec cPL was performed and was within normal limits at 47 ug/L. A urinalysis revealed a USG of 1.027, 2+ proteinuria and occasional granular casts. A *Coccidioides immitis* IgG and IgM antibody screen and titer was negative. A reticulocyte panel was mildly regenerative (reticulocyte count 157050 cells/uL). A Coomb's test and saline slide agglutination test were negative. Pleural fluid analysis revealed a suppurative exudate with no evidence of bacteria or fungal elements. Anaerobic, aerobic and fungal cultures of the pleural fluid yielded no growth. Cytology of the cutaneous wounds and the non-healing bite wound revealed a predominant population of neutrophils with no identifiable organisms.

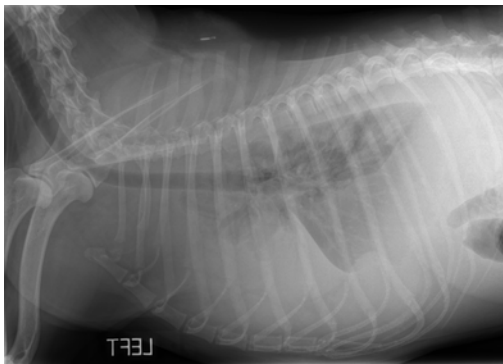


Figure 2. Left lateral thorax. Pleural fluid with retraction of lung lobes and irregular margination of lung ventrally.

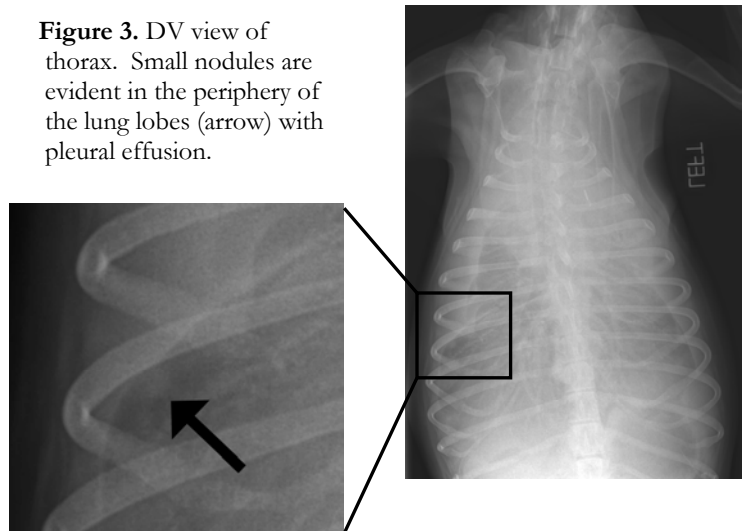


Figure 3. DV view of thorax. Small nodules are evident in the periphery of the lung lobes (arrow) with pleural effusion.

Diagnostic Imaging: Thoracic radiographs were obtained at presentation and revealed a large volume pleural effusion with retraction of the lung margins. Ventrally, the lung margin was irregular with evidence of air bronchograms superimposed over the cardiac silhouette on the right side. Questionable small nodules were evident in the peripheral lung field (see figure 3). An abdominal ultrasound was performed; the only abnormality was a mildly thickened gallbladder wall, likely due to hypoproteinemia with resulting gallbladder wall edema. A thoracic ultrasound was performed after pleural fluid was removed. A few small, hypoechoic lesions were found on the surface of the lungs that were consistent with the suspected nodularity of the lungs on radiographs. Cardiac structure and function appeared normal.

Diagnosis: Sterile pleural effusion, small pulmonary nodules, sterile nodular panniculitis

Treatment/Management: Bilateral thoracocentesis was performed. Approximately 1 liter of serosanguinous fluid was removed. Lady Bug was kept in oxygen for 48 hours and started on intravenous Normosol R and hetastarch. Medications included enrofloxacin 5mg/kg IV q 12 h, dexamethasone SP 0.35 mg/kg IV q 24 h, Cerenia 1mg/kg SC q 24 h, fluconazole 100 mg PO q 12 h, sucralfate 1 g PO q 6 h and misoprostol 50 mcg PO q 12 h. The patient's condition improved after the initial corticosteroid dose, and the pleural fluid did not progress. Lady Bug was discharged on gastrointestinal therapeutic medications, antibiotics, antifungals and prednisone at 10mg PO q 24 h.

One week later Lady Bug presented for a recheck. Her attitude, strength and appetite had improved. The wound over her left flank was still open and very large. The oozing wounds over her body were forming scabs and slowly starting to heal. Thoracic ultrasound revealed resolution of the pleural fluid, and the small nodules on the surface of the lungs were still present. Her prednisone dose was increased to 20mg in the morning and 10 mg in the evening (about 2 mg/kg/day). Blood work revealed a neutrophilia (43,428 cells/uL), monocytosis (7896 cells/uL) and hematocrit of 27.9% with slight regeneration. A urinalysis showed no evidence of protein or casts. Repeat thoracic radiographs were not taken at this time due to financial constraints.

Lady Bug returned two weeks later for another recheck. The wound over her left flank had started to form granulation tissue and was starting to decrease in size. Bloodwork revealed a neutrophilia (31,332 cells/uL), hematocrit 37.8% and monocytosis (1865 cells/uL). She then returned one week later. A thoracic ultrasound revealed two small pulmonary nodules on the left peripheral lung lobes and one on the right side, all measuring less than 1 cm in size. Two weeks later the wound on her left flank was healing well. A small mass over her left ileum was aspirated and revealed mainly fat with few red blood cells and a subjective increased neutrophil number. The prednisone dose was slowly tapered over 1.5 months to 5mg PO every other day. The oozing skin wounds started to recur at this lower prednisone dose, so the prednisone was increased to 5mg PO once daily; and the lesions rapidly resolved. By the next exam the wound on the left flank was completely contracted and healed. Prompted by a recent report of Bartonella associated panniculitis in dogs we started Lady Bug on doxycycline at 100mg PO twice daily.¹ Enrofloxacin was used initially in her treatment and could also have eradicated a Bartonella infection. The owners declined PCR testing for Bartonella due to financial constraints. One of Lady Bug's skin wounds opened up while on the doxycycline after 6 days, and the treatment was discontinued.

Discussion: Sterile nodular panniculitis is thought to result from a compromise of the adipose tissue vasculature.² Interruption of the nutrient arterial supply results in lobular panniculitis or diffuse degeneration of fat lobules. Disruption of the venous system results in alterations of the fibrous septa and peripheral portions of fat lobules causing septal panniculitis. These inflammatory processes lead to adipocyte lysis and death which provokes a histiocytic or granulomatous response.² At this time sterile nodular panniculitis is considered an idiopathic inflammatory disease of subcutaneous fat tissues. It has been associated with numerous systemic illnesses including lupus erythematosus, drug reactions, trauma, pancreatic neoplasia and pancreatitis.³

This condition is rare in dogs and cats. Lesions are characterized by one or more subcutaneous small nodules that may ulcerate or drain a yellow, oily fluid.² The lesions can occur anywhere on the body and may wax and wane.² Patients often have concurrent anorexia, depression and a fever. Differentials include bacterial, mycobacterial or fungal infections, a foreign body reaction, drug reaction, post injection reaction, systemic lupus erythematosus or neoplasia. Treatment involves surgical excision for single lesions, or, for multiple lesions, tetracycline and niacinamide, cyclosporine, prednisone and tacrolimus.⁴

Pleural effusion in dogs can be caused by various diseases. Transudative and modified transudative pleural effusion can be due to hypoalbuminemia, right sided heart failure, pericardial disease, a diaphragmatic hernia and neoplasia.⁵ Exudative pleural effusion can be due to neoplasia, a chronic diaphragmatic hernia, lung lobe torsions, lymphatic obstruction or leakage, and an infectious process.⁵ Lady Bug had an exudative pleural effusion, so even though she was hypoalbuminemic there was likely another inflammatory cause for the exudative pleural effusion.

In humans systemic autoimmune diseases can affect the pleura. Collagen vascular diseases (of which rheumatoid arthritis and systemic lupus erythematosus (SLE) are the most common) are immunologically mediated inflammatory diseases that affect the pleural cavity.⁶ The pleura is a continuous membrane consisting of visceral and parietal compartments. Mesothelial cells cover the pleura. Under this layer is the sub-mesothelial layer consisting of basement membrane proteins, type IV collagen and laminin, type I and III collagen, fibronectin and elastin fibers.⁶ Humans can develop rheumatoid pulmonary nodules that generally involve the visceral pleura and can lead to pleural effusion.⁶ Characteristic features of these nodules include fibrinoid necrosis, palisading

cells, lymphocyte and plasma cell infiltration.⁶ In humans, nodular panniculitis is associated with connective tissue diseases, immune-mediated disorders, pancreatic diseases, or infections.⁶ If connective tissue disorders in humans can lead to nodular panniculitis and pleural effusion then we postulate that the same could be true in a dog. Lady Bug is presumed to have an immunological disease that led to sterile nodular panniculitis, small pulmonary nodules and a resulting sterile pleural effusion that has all resolved with immunosuppressive therapy. Pulmonary biopsies, either antemortem or postmortem, would be required to provide further supportive evidence. Further diagnostics such as ANA and rheumatoid factor titers would have been helpful; however, financial constraints limited our diagnostics to the most crucial ones.

References:

- 1) Cross, J.R. et al. Bartonella-Associated Meningoradiculoneuritis and Dermatitis or Panniculitis in 3 dogs. *Journal of Veterinary Internal Medicine*. 2008; 22: 674-678.
- 2) Ackerman, L.J. Canine Nodular Panniculitis. *The Compendium on Continuing Education* Vol 6, No 9, September 1984, pp. 818-823.
- 3) Mellanby, R.J, et al. Panniculitis associated with pancreatitis in a cocker spaniel. *Journal of Small Animal Practice* 2003; 44: 24-28.
- 4) Kano, R, et al. Systemic Treatment of Sterile Panniculitis with Tacrolimus and Prednisolone in Dogs. *Journal of Veterinary Medical Science* 2005; 68(1): 95-96.
- 5) Ettinger, Feldman. *Textbook of Veterinary Internal Medicine. Diseases of the dog and cat.* 6th ed. 2005, Elsevier Inc. pp. 204-207.
- 6) Aiello, M, et al. Pleural Involvement in Systemic Disorders. *Current Drug Targets - Inflammation and Allergy* 2004; 3: 441-447.