



CANINE HYPERADRENOCORTICISM AND PSEUDOMYOTONIA

Case Report
Michele Laurenson, DVM

Reviewed by
THERESA ORTEGA, DVM, DIPLOMATE ACVIM

Signalment:

“Gracie” 6 year old female spayed Dachshund

Discussion:

Over a two month period, Gracie began losing hair and developed a distended abdomen. In addition, she was panting excessively, having accidents in the house and drinking and urinating more than normal. An ACTH stimulation test performed 4/22/2005 revealed a pre cortisol level of 5.4 ug/dL and post of 37.8 ug/dL, consistent with hyperadrenocorticism. An abdominal ultrasound performed 8/13/2005 revealed a large hyperechoic liver with bilaterally enlarged adrenal glands.

Her owners also noted stiff hind limbs and a wide-based stance, and Gracie was having difficulty walking and going up stairs.

On physical exam, she had generalized patchy alopecia and a moderately distended abdomen. Her skin was thin with ventral hyperpigmentation. She was ambulatory, but had bilateral pelvic limb extensor rigidity with prominent hind limb and paraspinal muscular development, atypical of dogs with hyperadrenocorticism. Conscious proprioception in the pelvic limbs was delayed, but present. She had no evidence of spinal pain, nor other neurologic abnormalities.

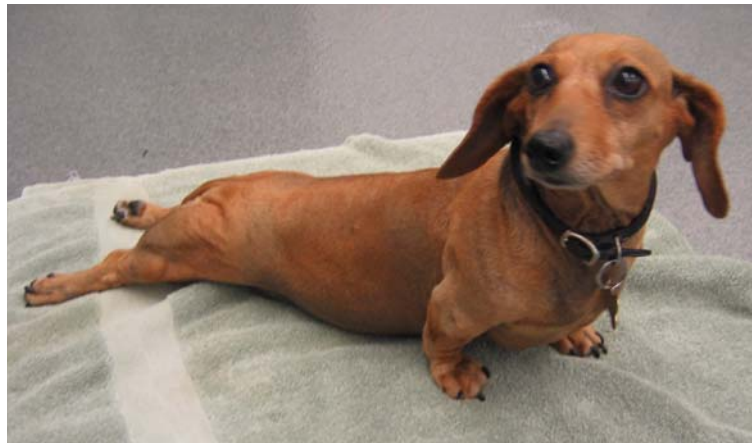

Figure 1. Hind limb rigidity and hypertrophy in a dog with hyperadrenocorticism.

Clinical Signs:

The classic clinical signs of canine hyperadrenocorticism include polydipsia and polyuria (80-91%), alopecia (60-74%), pendulous abdomen (67-73%), hepatomegaly (51-67%), polyphagia (46-57%), muscle weakness (14-57%), muscle atrophy (35%), panting (30%) and hyperpigmentation (23-30%).¹ Others include anestrus, testicular atrophy, calcinosis cutis and facial nerve paralysis.

In rare cases of hyperadrenocorticism (<1%), dogs develop a myotonia (pseudomyotonia) coincident with the onset of Cushing's disease.² This syndrome is characterized by muscular hypertrophy and a stiff disabling gait (particularly of the pelvic limbs), in contrast to the typical clinical signs of muscular atrophy and weakness. The muscular rigidity may be so pronounced that the dog is non-ambulatory, and flexion of the hindlimbs may not be possible even under general anesthesia.³ In addition to the pelvic limbs, myotonia of the epaxial and thoracic limbs may also be apparent. Generally these animals are nonpainful and have an otherwise unremarkable neurologic examination. Percussion of the muscles may also produce a characteristic “myotonic dimple.”³

Etiology:

In dogs with naturally occurring hyperadrenocorticism, 80-85% have pituitary-dependent hyperadrenocorticism (PDH), while the remaining (15-20%) have a functional cortisol-secreting adrenal tumor (AT). Most dogs with PDH have small ACTH-secreting pituitary adenoma; however, some develop “macrotumors” that lead to a variety of central nervous system signs due to a space-occupying lesion within the brain. Iatrogenic Cushing's can be caused by oral or cutaneous administration of corticosteroids.

Myotonia is due to sustained contractions of muscle fibers. A variety of inherited myotonic disorders are seen in dogs, horses, mice and goats, and are due to defects in the muscular cell membrane leading to repetitive depolarization.³ Secondary myotonia has also been seen with both metabolic and inflammatory myopathies, including hypothyroidism, hyperadrenocorticism and toxoplasmosis.^{3,4} The pathophysiology of hyperadrenocortical myotonia is unknown, and may occur with either PDH or iatrogenic hyperadrenocorticism. Some have suggested that pseudomyotonia in French Poodles is not associated with hyperadrenocorticism, but is a separate, possibly genetic disease.⁵

Diagnosis:

Diagnosis of Cushing's disease consists of two major steps: (1) Screening tests - Establishing the presence of hyperadrenocorticism. (2) Differentiating tests - Determining if it is pituitary dependent or an adrenocortical tumor.

Screening tests include the ACTH stimulation test, urine cortisol:creatinine ratio (UCC) and the low dose dexamethasone suppression test (LDDST). The ACTH stimulation test has good specificity (85-90%) but lower sensitivity (60-85%).¹ Approximately 40% of dogs with PDH will have a post stimulation cortisol level within the normal range. UCC is highly sensitive, but not specific; a variety of conditions may cause abnormally elevated levels of urine cortisol. The LDDST has the advantages of both high sensitivity (85-95%) and specificity (70-75%).¹

Differentiating tests include the LDDST, high dose dexamethasone test (HDDST), plasma endogenous ACTH levels and abdominal ultrasound. Approximately 60-65% of dogs with PDH will suppress with the LDDST, while dogs with an AT have elevated cortisol levels at 4 and 8 hours. If PDH is suspected, and no suppression is observed, a HDDST may be performed; approximately 75-80% of dogs with PDH will suppress with the high dose. An ACTH level is also a good means of differentiating PDH from an adrenal tumor, but the test is expensive, and results can take as long as 2 weeks to be reported. Ultrasonography is also a valuable tool, but hormonal testing is still necessary to prove if an animal has PDH or a functional adrenal tumor.

Diagnosis of myotonia consists of electromyography (EMG) analysis and muscle biopsies. Myotonic EMG potentials are high frequency discharges that wax and wane, producing a characteristic "dive-bomber" sound. Some have also reported that many dogs with hyperadrenocorticism can have pseudomyotonic potentials, which do not wax and wane in frequency and amplitude, and have a characteristic high-pitched sound like a motor.⁶ Muscle biopsies may reveal histologic findings characteristic of a steroid myopathy, including fiber size variation, fiber atrophy (especially type II), subsarcolemmal masses, fiber splitting and focal necrosis.⁶

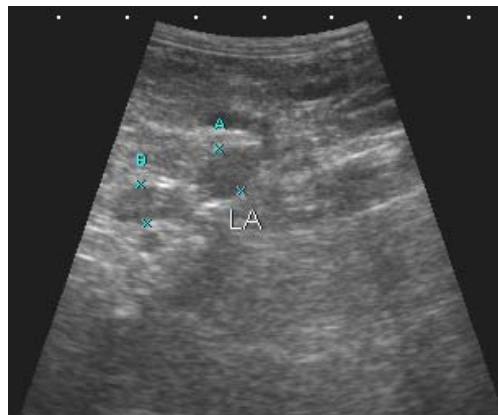


Figure 2. Enlarged adrenal gland in a dog with PDH.

Management:

The primary treatment of PDH is medical management with mitotane (o,p'-DDD, Lysodren) or trilostane. Lysodren, a derivative of DDT, destroys the adrenal cortex (zona fasciculata and zona reticularis), partially sparing the zona glomerulosa, the site of mineralocorticoid production. Side effects include lethargy, weakness, anorexia, vomiting, diarrhea and/or ataxia. Trilostane, a relatively new treatment, inhibits the enzyme 3-beta-hydroxysteroid dehydrogenase, inhibiting progesterone production and its products including cortisol, aldosterone and androstenedione. The adverse effects of trilostane are uncommon, and usually reversible with discontinuation of the drug. However, it can be more expensive and is generally administered once or twice daily.

Treatment of the myotonia is initially directed at treating the underlying hyperadrenocorticism. In addition to physical therapy, cell membrane stabilizing medications including procainamide at 12.5 mg/kg PO BID have been reported to be beneficial at reducing muscular stiffness in dogs with myotonia.⁶ Supplementation with L-carnitine and coenzyme Q10 may also be helpful in dogs with steroid myopathies.

Prognosis:

The prognosis of dogs with PDH is good, with an average survival time of 2 years after diagnosis. Typically, 80% of dogs respond favorably to medical management with trilostane or mitotane. However, long-term therapy is required, with regular re-evaluation of an ACTH stimulation test. Unfortunately, in many dogs with pseudomyotonia, the clinical signs may not resolve even with appropriate treatment of the Cushing's disease.

Follow-up:

Gracie was initially treated with trilostane 30 mg PO SID. A two week recheck exam after initiation of therapy revealed persistence pelvic limb and epaxial myotonia; however, Gracie was otherwise responding well with a decrease in her clinical signs of PU/PD. A recheck ACTH stimulation test revealed a pre cortisol level of 2.9 ug/dL and a post of 3.9 ug/dL.

References:

1. Reusch, CE. "Hyperadrenocorticism." *Textbook of Veterinary Internal Medicine*, Ettinger, Feldman. 6th Ed., Saunders, Philadelphia, 2005:1592-1610.
2. Feldman EC, Nelson RW. *Canine and Feline Endocrinology & Reproduction*. 3rd Ed., Saunders, Philadelphia, 2004:252-353.
3. Swinney GR, Foster SF, Church DB, Malik R. Myotonia associated with hyperadrenocorticism in two dogs. *Aust Vet J* 1998;76: 722-4.
4. Oliver JE, Lorenz MD, Kornegay JN. *Handbook of Veterinary Neurology*. 3rd Ed., Saunders, Philadelphia, 1997:262-263
5. Siliart B, Marouze C, Martin L, Gayet C. Pseudomyotonia Associated with Hyperadreno-Corticism in the French Poodle: 151 Clinical Cases (1993-2000). 12th ECVIM-CA/ESVIM Congress.
6. Vite CH. Braund's Clinical Neurology in Small Animals. International Veterinary Information Service, Ithaca, NY (www.ivis.org), 2005