BABESIA GIBSONI

Case Report
Jennifer L. Kelly, DVM

REVIEWED BY
CARRIE A. PALM, DVM, DACVIM

Signalment:
"Scrappy"
14 month, MN, Pit Bull Terrier
BCS 4/9

History:
Scrappy was presented for evaluation after a 3 day history of progressive lethargy, weakness and anorexia. Initial diagnostic workup by his primary veterinarian included a complete blood count (CBC), Chemistry profile, Coombs test and testing for Ehrlichia, Heartworm (HW) and Lyme disease. The CBC revealed a severe, non-regenerative anemia with marked spherocytosis. The Chemistry profile revealed increased ALP 272 U/L and AST 88 U/L, and hyperbilirubinemia (total bilirubin 3.1 mg/dL). The Coombs test and testing for Ehrlichia, Lyme and HW were negative. A blood transfusion was administered and Scrappy was administered Baytril (6.5 mg/kg PO SID), prednisone (1 mg/kg PO BID) and doxycycline (7 mg/kg PO BID). Scrappy was in a dog fight with another pit bull 2.5 months prior to presentation. He was a rescue dog (previous medical history unknown). Scrappy then presented to VMSG for further evaluation.

Clinical Exam:
On initial examination, Scrappy was weak, with pale, icteric mucous membranes, tachycardia (HR 152) and weak femoral pulses. A grade II/VI systolic heart murmur was heard.

Laboratory Findings:
- PCV/TS (on presentation): 10%, 7.8 g/dL; PCV/TS (at discharge): 24%, 6.6 g/dL
- Slide agglutination (macroscopic, microscopic): positive throughout hospitalization (after initial blood transfusion)
- Chemistry profile (4 days into hospitalization): total bilirubin 0.6 mg/dL, increased ALP 457 U/L, hypercholesterolemia 420 mg/dL
- CBC (4 days into hospitalization): neutrophilia with left shift (seg 20,999/uL, bands 1012/uL), monocytosis (512/uL), thrombocytosis (512,000/uL), regenerative anemia (Hct 24%, reticulocytes 585,900/mm^3)
- Babesia canis, Babesia gibsoni, Ehrlichia PCR (peripheral blood): negative
- Blood smear cytology (ear prick): positive for Babesia gibsoni
- Babesia gibsoni PCR (ear prick blood smear): positive

Diagnostic Imaging:
Abdominal radiographs: unremarkable (no evidence of metallic foreign material)

Diagnosis:
Babesia gibsoni infection with evidence of a secondary IMHA (spherocytosis, hyperbilirubinemia, and severe anemia with a normal TS were all noted prior to the first blood transfusion; positive slide agglutination was not noted until after first blood transfusion).

Treatment/Management:
Scrappy was hospitalized in the ICU and was administered a total of 24 ml/kg of pRBCs during hospitalization, to treat for the severe anemia. Initial therapy included intravenous fluids, prednisone (1 mg/kg PO BID), cyclosporine (5 mg/kg PO BID), aspirin (0.5 mg/kg PO SID), enoxaparin (1 mg/kg SC TID), famotidine (0.5 mg/kg PO BID), doxycycline (5 mg/kg PO BID) and maripotant (1 mg/kg SC SID). Three days into hospitalization, azithromycin (9.5 mg/kg PO SID) was started and the cyclosporine was discontinued due to concern for possible Babesia gibsoni infection. A blood smear from an ear prick was submitted for cytological review. A peripheral blood sample was also submitted for a Babesia gibsoni, Babesia canis and Ehrlichia PCR. Cytology from the ear prick blood smear was positive for Babesia gibsoni. The Babesia and Ehrlichia PCR on peripheral blood were negative. Given the discrepancy, PCR was then performed using the slide from the ear prick blood smear on which Babesia gibsoni organisms had been visualized. The PCR from the ear prick blood smear was positive for Babesia gibsoni. Scrappy was started on atovaquone (13 mg/kg PO TID) and prednisone was tapered to 0.5 mg/kg PO BID. At the time of discharge Scrappy's PCV/TS were stable (PCV 24%, TS 6.6 g/dL). He was discharged on oral medications (prednisone, famotidine, atovaquone, azithromycin, and aspirin) with the plan to taper prednisone quickly, while continuing atovaquone and azithromycin.

Follow-up Care: Following initial discharge Scrappy was doing well at home and his PCV/TS were stable. His prednisone was tapered to 0.5 mg/kg PO SID. On recheck examination (5 weeks post discharge), his CBC and Chemistry profile were normal. His prednisone was tapered further. The owner discontinued the atovaquone 1 week prior and the azithromycin 3 weeks prior to recheck.

Figure 1

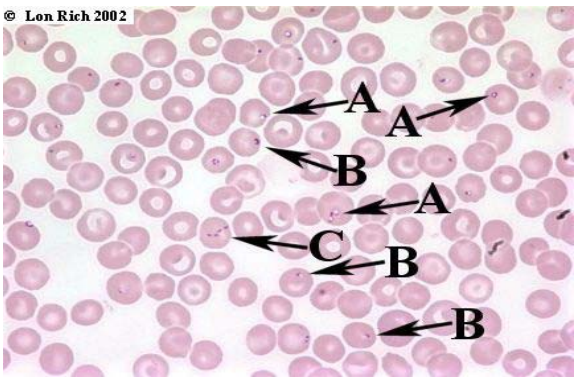

Figure 2

.

Discussion: Babesia gibsoni is a hemoprotozoan parasite that has clinical significance in dogs. Microscopically, the parasite forms small, round to oval piroplasms measuring 1-2.5 um in diameter [4]. The majority of Babesia gibsoni infections from dogs in the United States have been American Staffordshire Terriers and American Pit Bull Terriers [3]. The high prevalence of babesiosis among these breeds is likely a result of breed susceptibility as well as environmental factors that lead to increased exposure [6]. There are many possible modes of transmission of Babesia gibsoni infection. In the US, Rhipicephalus sanguineus, the brown dog tick, is the suspected vector [2, 3]. Ticks must feed for 2-3 days for dogs to become infected. Upon infection sporozoites are released into circulation [2]. The organism attaches to RBC membranes and is engulfed by endocytosis [2]. Binary fission occurs in the cytoplasm of the RBC and results in merozoites [2]. Ticks become infected with merozoites during feeding and can remain infective for multiple generations via transovarial and transstadial transmission [2]. Transplacental transmission from bitch to offspring is also likely to occur, however, this has not yet been documented in a controlled study [3]. Babesia gibsoni is also likely transmitted by direct blood contamination; potential sources include dog fights and sharing of surgical instruments [3].

Clinical findings of infected dogs may include fever, lethargy, hemolytic anemia, thrombocytopenia, lymphadenopathy and splenomegaly. Anemia is typically due to both intravascular and extravascular hemolysis [2]. Secondary immune mediated destruction occurs due to parasitic antigens on the surface of red blood cells [2]. Coombs testing may be positive in up to 90% of symptomatic dogs [2]. Changes in the white blood cell line are variable. One study found transient profound neutropenia in some dogs, followed by a prolonged period of borderline neutropenia [4]. Most dogs that survive the initial parasitemia remain chronic carriers [5]. These dogs are at a risk for relapsing months to years after the initial infection, particularly under times of stress [5]. Long-term sequelae related to chronic immune stimulation may develop, such as polyarthritis and glomerulonephritis [5].

Diagnosis can be made based on microscopic evaluation of a blood smear, serology and PCR. Serology titers of >1:320 support a diagnosis of Babesia gibsoni infection [2, 6]. False negatives are possible as the antibody response typically takes 8-10 days to develop [2]. PCR can be used to identify the infective species as well as detect low levels of parasitemia. False negatives are possible when parasitemia levels are very low [2]. Blood collected from peripheral capillary beds, such as the ear tip or nail bed, may yield increased numbers of parasitized cells, as was the case with Scrappy [6]. In addition, erythrocytes adjacent to the buffy coat of centrifuged specimens are more likely to be infected as the organism is more likely to infect cells with higher levels of amino acids, nucleic acids and ATP [6].

Treatment for Babesia gibsoni can be problematic, as the infection is not typically cleared with standard Babesia therapies. A recent study showed that a combination therapy of atovaquone (13.3 mg/kg TID) and azithromycin (10 mg/kg SID) was a safe and effective treatment for Babesia gibsoni in dogs [1, 6]. Thus far, it is the only treatment for Babesia gibsoni that has resulted in elimination of infection or suppression of parasitemia below detectable limits [1, 6]. The use of glucocorticoids is controversial. In the acute stages it may help to reduce immune-mediated red blood cell destruction, however, long-term use may result in decreased splenic clearance of the organism [5, 6]. Prevention of Babesia gibsoni infection is aimed at reducing exposure and includes tick control, sterilizing instruments used for tail docking and ear cropping, screening programs in breeding kennels, and prevention of dog fighting [2].

References:

1) Birkenheuer AJ, Levy MG, Breitschwerdt EB. Efficacy of combined atovaquone and azithromycin for therapy of chronic *Babesia gibsoni* (Asian genotype) infections in dogs. J *Vet Intern Med* (18): 494-498, 2004.
2) Boozer, L, Macintire, D. *Babesia gibsoni*: An emerging pathogen in dogs. Compendium (2): 33-42, 2005.
3) Macintire, DK, Boudreaux, MK, West, GD, Bourne, C, Wright, JC, Conrad, PA. *Babesia gibsoni* infection among dogs in the southeastern United States. *JAVMA* (220, 3): 325-329, 2002.
4) Meinkoth, JH, Kocan, AA, Loud, SD, Lorenz, MD. Clinical and hematologic effects of experimental infection of dogs with recently identified *Babesia gibsoni*-like isolates from Oklahoma. *JAVMA* (220, 2): 185-189, 2002.
5) Stegeman, JR, Birkenheuer, AJ, Kruger, JM, Breitschwerdt, EB. Transfusion-associated *Babesia gibsoni* infection in a dog. *JAVMA* (222, 7): 959-963, 2003.
6) Taboada, J, Lobetti, R. *Babesiosis*. Infectious Diseases of the Dog and Cat, 3rd Edition. Elsevier Inc, 2006: 722-736.

Figures: Figure 1: Scrappy 2 days prior to discharge. Figure 2: Dog blood with many small ring-like structures in the erythrocytes (A). These are BABESIA GIBSONI organisms. Some of the parasites have a small eccentrically placed nucleus (B) and look "diamond ring like" while others appear like small rods (C).